

# Acute lower extremity ischaemia

## Acute lower limb ischaemia is a surgical emergency.

N G Naidoo, MB ChB, FCS (SA); P S Rautenbach, MB ChB; D Kahn, MB ChB, FCS (SA), ChM

Department of Surgery, Groote Schuur Hospital and University of Cape Town, Cape Town, South Africa

Corresponding author: N Naidoo (nadraj.naidoo@uct.ac.za)

Acute lower extremity ischaemia (ALEXI) is often defined as a sudden loss of perfusion to the lower extremity/extremities of less than 14 days' duration, resulting in variable ischaemic clinical manifestations and the potential risk of limb loss. The incidence is ~1.5 cases per 10 000 persons per year. Acute ischaemia threatens limb viability because there is insufficient time for new blood vessel growth to compensate for loss of perfusion.<sup>[1]</sup> Diagnostic errors and treatment delays are unforgiving, and may result in loss of limb or life. In-hospital amputation rates may range from 10% to 40% in Western series. Rapid referral to a dedicated vascular service for assessment and expeditious treatment is mandatory. A matter of a few hours can mean the difference between a major amputation, limb salvage or death. Approximately 15 - 20% of patients die within the first year after ALEXI, with most of these deaths occurring in the peri-operative period.

### Aetio-pathology

#### Embolism

Approximately 80% of embolic ALEXI is cardio-embolic. Most of the pathology currently relates to thrombus formation in the left atrial appendage in a patient with atrial fibrillation. Other cardiac causes include valvular heart disease, prosthetic heart valves, post-myocardial infarction, ventricular aneurysm, atrial myxoma, and paradoxical embolism in a patient with a patent foramen ovale.

Arterio-embolic sources are less common and include aortic aneurysms, complicated aortic plaque disease, adherent aortic thrombus, peripheral aneurysms (iliac, femoral, and popliteal), and complicated peripheral arterial plaque disease.

Embolism resulting in ALEXI is associated with large emboli (macro-embolism). These tend to impact at arterial bifurcations, the commonest site being the common femoral bifurcation. A portion of this embolus may fragment and embolise distally to

occlude the popliteal trifurcation. A very large embolus may impact at the aortic bifurcation ('saddle embolus') (Table 1).<sup>[2]</sup>

#### Thrombosis

The dominance of acute graft thrombosis versus native artery thrombosis will depend on the extent of vascular bypass graft utility in a particular community. The causes of graft thrombosis include neo-intimal hyperplasia, usually at the anastomotic regions, or progression of native artery disease proximal or distal to a graft. Native artery thrombosis generally occurs in severely diseased peripheral arteries.<sup>[3]</sup> Patients with graft or

native artery thrombosis may have severe associated comorbidities, e.g. cardiac failure or dysfunction that may not only contribute to the development of ALEXI but which may need to be optimised concurrently in the management algorithm to improve clinical outcomes. These comorbidities may be associated with a poor prognosis.

With an increasingly elderly population it is not unusual for patients to present with lower extremity cardio-embolism against a background of established peripheral arterial disease (PAD). In this setting the thrombus propagates not only proximal and

Table 1. Aetio-pathology of ALEXI

#### Embolism

- Cardio-embolism
- Arterio-embolism

#### Thrombosis

- Vascular graft thrombosis
- In-stent thrombosis
- Native artery thrombosis
- Peripheral aneurysms, e.g. popliteal aneurysms (50% present with ALEXI)

#### Trauma

- Blunt (e.g. knee dislocation)
- Penetrating (stab/gunshot)

#### Iatrogenic injury

- Post-catheterisation (e.g. post-diagnostic/interventional angiography)
- Following lower extremity surgery in the proximity of major vessels

#### Malperfusion

- Aortic dissection
- Isolated peripheral arterial dissection

#### Thrombophilia

- Unexplained graft occlusion
- Occlusion of normal native arteries

Table 2. Clinical features discriminating embolic from thrombotic ALEXI

Clinical features	Embolic	Thrombotic
Severity	Marked, rapidly progressive	Less severe, slowly progressive
Onset	Minutes/hours	Generally days
Contralateral leg pulses	Present	Absent
Femoral arteries palpated	Soft, tender	Hard, calcified
Dystrophic limb features	Absent	Present
Cardiac abnormalities	Present	Generally absent
Iliac/femoral bruits	Absent	May be present
History of claudication	Absent	Present

distal to an embolus, but also proximal and distal to the segmental arterial occlusive disease. Limb salvage is generally poor.

It is not unusual for ALEXI occasionally to be confounded by a thrombophilia (e.g. the anti-phospholipid syndrome). These patients may have a family history of arterial or venous thrombosis, may have recurrent thrombotic episodes, or may be associated with unexplained graft or normal native artery thrombosis.

### Approximately 80% of embolic ALEXI is cardio-embolic.

#### Clinical appraisal

The diagnosis of ALEXI is formulated based on a carefully taken case history and the presence of classic clinical features. These include the presence of any one or more of the following 6 'Ps': pain, paraesthesia (or anaesthesia), paresis (or paralysis), pallor, pulselessness, and poikilothermia ('perishing with the cold'). There are certain features that enable clinical discrimination between embolic or thrombotic ALEXI (Table 2).

In embolic ALEXI the foot is cold and pale as a cadaver. It may be dusky, with digital or dermal mottling, which may extend proximally for a variable distance depending on the level of arterial occlusion. There are generally no trophic changes associated with PAD. Examination of the foot may reveal 'venous guttering' (collapsed veins with grooving of the skin) (Table 3).

The presence of calf tenderness (especially with passive dorsiflexion of the big toe or foot) may herald advancing limb ischaemia. Other ominous signs of advanced ischaemia include bluish dermal mottling that blanches with pressure. Fixed skin staining (non-blanching) and rigidity of calf compartments ('rigor mortis'/inability to dorsiflex the foot) generally point to established tissue necrosis and a non-salvageable leg. Revascularisation in the latter setting may result in acute renal failure (the myo-nephropathic syndrome) and/or other systemic manifestations of the ischaemic-reperfusion syndrome.

The severity of ALEXI is categorised according to the clinical presentation and prognosis (Table 3).

#### Diagnostic algorithm

All patients with ALEXI require basic blood tests, incorporating a full blood count, urea and electrolytes, creatinine levels, blood sugar, and clotting profile, as well as an ECG and a chest X-ray. Young patients (<50 years) with thrombotic ALEXI will require a thrombophilia screen to exclude hyperhomocysteinaemia or the antiphospholipid syndrome, before the

**Table 4. Contraindications to CDT\***

##### Absolute contraindications

- Current active bleed/bleeding disorders
- Recent haemorrhagic stroke
- ALEXI with compartment syndrome

##### Relative contraindications

- Major surgery or trauma within 2 weeks
- Recent gastrointestinal bleed within 2 weeks
- Intracranial or spinal surgery within 3 months
- Head injury within 3 months
- Established cerebrovascular event (including transient ischaemic attack) within 2 months
- Severe, poorly controlled hypertension
- Recent puncture of non-compressible vessel
- Pregnancy
- Diabetic haemorrhagic retinopathy
- Recent eye surgery
- Liver failure
- Cardiopulmonary resuscitation in the last 2 weeks
- Bacterial endocarditis

\*Adapted from Rajan DK, Patel NH, Valji K, *et al.* Quality improvement guidelines for percutaneous management of acute limb ischemia. *J Vasc Interv Radiol* 2009;20(7 suppl):S208-218.

**Table 3. Recommended standards for lower extremity ischaemia\***

Category	Doppler signals		Findings	
	Sensory loss	Muscle weakness	Arterial	Venous
I. Viable	None	None	Audible	Audible
II. Threatened				
IIa. Marginally threatened	Minimal (toes)	None	Inaudible	Audible
IIb. Immediately threatened	More than toes Severe rest pain	Mild/ moderate	Inaudible	Audible
III. Irreversible	Profound/ anaesthetic	Profound/ paralysis (rigor)	Inaudible	Inaudible

\*Adapted from Rutherford RB, Baker JD, Ernst C, *et al.* Recommended standards for reports dealing with lower extremity ischaemia. *J Vasc Surg* 1997;26:517-538.

administration of heparin. Screening for human immunodeficiency virus (HIV) is also advisable in young patients. A fasting lipogram or glycosylated haemoglobin ( $\text{HbA}_{1c}$ ) may be requested electively where appropriate.

A hand-held Doppler assessment of foot vessels for signals is essential. Arterial signals may be weak or absent. An ankle pressure  $<50$  mmHg suggests severe ALEXI. In addition, absence of venous signals suggests advanced ALEXI.

Classic embolic ALEXI is a clinical diagnosis and generally diagnostic imaging is not necessary. Given the rapidly progressive course of this condition, expeditious embolectomy is advised. On-table angiography is required to ensure completeness of the embolectomy procedure. An echocardiogram and/or multi-detector computed tomography angiogram (MDCTA) of the chest and abdomen may be requested postoperatively to confirm a cardiac or an aorto-iliac source of embolism.

In patients with thrombotic ALEXI there is usually time for diagnostic imaging. This is only appropriate in Rutherford class I, IIa or III ALEXI. Duplex ultrasound (DUS) is a useful modality to evaluate the lower extremity arteries. The saphenous veins may be evaluated to determine suitability as a conduit should an emergency bypass procedure be required. Other imaging modalities include MDCTA (chest, abdomen and lower extremities) and contrast-enhanced magnetic resonance angiography (CEMRA). A diagnostic conventional digital subtraction angiogram (DSA) may also be performed, especially if the candidate is deemed suitable for catheter-directed thrombolytic therapy.

In patients with rapidly progressive ALEXI or Rutherford class IIb ALEXI, time-wasting angio-imaging is inappropriate. The patient should have an on-table angiogram in theatre with a view to expeditious revascularisation. This is currently possible with the wide availability of hybrid theatres.

### Initial management

The basic principles related to medically optimising the patient apply. Adequate analgesia should be prescribed. Avoid intramuscular opiates if thrombolytic therapy is being considered. A stat dose of aspirin, 325 mg, is indicated. The administration

of intravenous heparin on first assessment cannot be over-emphasised. This is to prevent clot propagation and preserve important collaterals. An induction dose of  $\sim 100$  U/kg is given intravenously. Avoid subcutaneous unfractionated heparin or low molecular heparin in the acute treatment phase – it is difficult to titrate an adequate effect. If there are likely to be delays in treatment, e.g. diagnostic imaging, patient optimisation, consider an intravenous heparin infusion. We inject  $\sim 25\,000$  units in 200 ml of normal saline and infuse this at 8 - 10 ml/h titrated to maintain a partial thromboplastin time (PTT) of 80 - 120 seconds. The PTT levels may need to be checked frequently (6-hourly) to determine the required infusion rate.

**Diagnostic errors and treatment delays are unforgiving, and may result in loss of limb or life.**

### Treatment options

Treatment algorithms employ three complementary treatment modalities in the management of ALEXI. It is not unusual for more than one, if not all modalities, to find utility in a given patient:

1. Medical treatment (anticoagulation)
2. Percutaneous endovascular techniques
  - catheter-directed thrombolysis (CDT)
  - percutaneous mechanical thrombectomy (PMT)

### 3. Surgery

- transfemoral embolectomy
- transfemoral thrombectomy
- intraoperative thrombolysis
- intraoperative angioplasty and/or stenting
- vascular bypass procedures
- endarterectomy and patch-plasty
- hybrid procedures.

### Anticoagulation

Anticoagulation with warfarin (vitamin K antagonist) is a feasible option in ALEXI patients with Rutherford I presentation or acute-onset claudication, especially if a patient is a poor candidate for revascularisation. This allows the treatment protocol to be supplemented by exercise therapy and optimum medical treatment. This approach enables the performance of a revascularisation procedure (operative or endovascular) weeks or months later, should the clinical profile not improve.

Anticoagulation is generally required after embolectomy, the duration depending on the aetiology. Patients with indeterminate embolic aetiology require anticoagulation for one year. Patients diagnosed with a thrombophilia require long-term anticoagulation.

### Embolectomy

Transfemoral embolectomy for ALEXI may be performed under local, regional or general anaesthesia via a small groin incision. A small transverse femoral arteriotomy facilitates proximal and distal transfemoral embolectomy using an appropriately sized Fogarty balloon catheter. Intraoperative



Fig. 1. Angio-imaging of the popliteal trifurcation before and after selective balloon embolectomy.

angio-imaging currently enables super-selective embolectomy of the crural vessels using an over-the-wire dual lumen Fogarty balloon catheter (Fig. 1).

### Endovascular interventions

The last 20 years has witnessed an evolution to minimally invasive percutaneous techniques to address thrombotic ALEXI. These procedures are generally performed in a cath-lab or angio-suite under local anaesthesia, and are indicated in patients with Rutherford IIa ischaemia (rarely in progressive Rutherford I ischaemia). Patients with Rutherford IIb ischaemia are generally excluded because of the advanced limb ischaemia mandating immediate surgical revascularisation. Two percutaneous endovascular modalities exist: CDT and PMT. Both procedures can remove the thrombus in a peripheral artery and unmask culprit lesions that may be addressed with angioplasty and/or stenting. Advances in PMT techniques suggest the feasibility even in select Rutherford IIb patients. This may be a consideration in poor surgical risk patients, especially in vascular centres where these facilities are available.<sup>[4]</sup>

A few observations deserve mention here:

- These techniques perform better in the femoro-popliteal segment (cf. the iliac or tibio-peroneal segments).
- These techniques perform better in thrombosed vascular grafts and thrombosed stents compared with thrombosed native arteries.

### Catheter-directed thrombolysis

CDT is a technique currently used to clear arteries, arterioles and capillary beds to restore and preserve perfusion to the lower extremity. Modern thrombolytic agents are plasminogen activators that convert thrombin-bound plasminogen to active plasmin, which in turn degrades fibrin to enable clot dissolution. Most centres currently use a recombinant tissue plasminogen activator (rt-PA), e.g. alteplase. The procedure is designed to deliver maximal doses of thrombolytic agent to the thrombus while simultaneously reducing systemic thrombolytic spill.

Patients are exposed to the risk of local and remote haemorrhagic complications and proper case selection is critical (Table 4). The success of CDT is determined by the ability of the angiographic catheter to cross a thrombosed

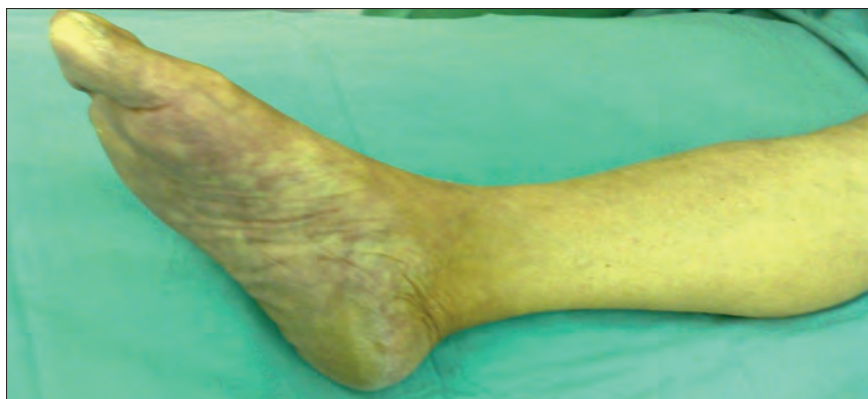

Fig. 2. Pale foot with bluish dermal staining. Note the collapsed veins.

segment ('guidewire and catheter traversal test'). Once crossed, the diagnostic catheter is replaced by a 6Fr thrombolysis infusion catheter with multiple side-holes. We use an induction dose of 1 - 10 mg of alteplase to 'lace' the thrombus (depending on the clot burden) and maintain an intra-clot infusion dose of 0.5 - 1 mg/h. We infuse 500 units of heparin per hour into the 6Fr sheath to prevent 'sleeve' thrombosis. We serially measure the aPTT and fibrinogen levels. Fibrinogen levels <2 g/dl are associated with bleeding complications and should direct cessation of the procedure.

Thrombolysis with urokinase, alteplase, streptokinase and reteplase has been investigated previously. Three large multi-centre randomised trials were published in the 1990s comparing thrombolysis to surgery for acute limb ischaemia (ALI).

The Rochester study<sup>[5]</sup> was a small study (114 patients) comparing urokinase with surgery. The 1-year amputation-free survival was significant: 75% in the urokinase arm v. 52% in the surgical arm (due largely to higher peri-operative mortality in the surgical arm).

The Thrombolysis for Ischaemia of the Lower Extremity (STILE) trial<sup>[6]</sup> was a large study (393 patients) comparing surgery with thrombolysis using alteplase or urokinase. For presentations less than 14 days the results were in favour of thrombolysis (amputation rates at 6 months: 11% v. 30% for surgery). The results favoured surgery for presentations after 14 days.

However, another large study (544 patients), the Thrombolysis or Peripheral Arterial Surgery (TOPAS) study, failed to show any significant difference in the peri-operative amputation-free survival or mortality rates. Similarly, there

was no difference in the 6-month amputation-free survival rates for r-urokinase v. surgery (71.8% v. 74.8%).<sup>[7]</sup>

A meta-analysis of randomised trials comparing catheter-directed thrombolytic therapy with surgery for ALI showed similar rates of limb salvage, but thrombolysis was associated with higher rates of stroke and major haemorrhage within 30 days.<sup>[8]</sup>

Complications of CDT include major bleeding (up to 12.5% in one study) and, less commonly, distal embolisation.

### Percutaneous mechanical thrombectomy

Simple aspiration catheters are available to aspirate thrombus, with or without the use of thrombolytic agents. Dedicated PMT devices mechanically disrupt and simultaneously aspirate thrombus material via a dedicated catheter system. They may be classified into hydro-dynamic or rotational systems. These devices may represent the best option in patients who are a high risk for surgery and are not suitable for CDT. Complications include distal embolisation, haemolysis and fluid overload with select devices. More compelling trials are required before these achieve competitive status.

### Surgical revascularisation

Surgical techniques include: balloon catheter embolectomy, transluminal thrombectomy, vascular bypass procedures, endarterectomy and patch-plasty, intraoperative thrombolysis and hybrid procedures (surgery and endovascular procedures, viz. angioplasty/stenting).

Transfemoral Fogarty catheter-based techniques are best suited for embolic disease or



thrombosed vascular grafts (usually prosthetic grafts). Grafts may need revision (operative or endovascular) or redo bypass procedures. Iliac native vessel thrombectomy generally produces good results; residual stenoses of >30% may be treated with a stent. Infra-inguinal native artery thrombosis generally responds poorly to balloon thrombectomy. Here bypass grafting defined by pre-operative or on-table angio-imaging is more appropriate. Occasionally a thrombosed common femoral artery may be treated by thrombectomy, endarterectomy and a patch angioplasty. Intraoperative thrombolysis is usually a last ditch measure to salvage or identify suitable infra-popliteal runoff (Fig. 3).

The results of surgical treatment are related to the degree of limb ischaemia at presentation and patient comorbidities. Amputation rates of 10 - 30% have been reported, including high peri-operative mortality rates (10 - 25%). Two-year limb salvage rates of 75% have been reported.

## Special considerations

### Ischaemic-reperfusion injury

Reperfusion of ischaemic muscles may produce myoglobinuria and acute renal dysfunction. Treatment measures include intravenous crystalloids to maintain a good urine output, diuretics, sodium bicarbonate, potassium shifting and renal dialysis.

### Fasciotomy

Four-compartment calf fasciotomy may be performed for three reasons:

- Diagnostic: the presence of two or more non-viable compartments renders the limb non-salvageable.
- Therapeutic: the patient has established features of compartment syndrome.

- Prophylactic: the risk of compartment syndrome following treatment for ALEXI is anticipated.

## Conclusion

The timeous diagnosis of ALEXI cannot be over-emphasised. Immediate heparinisation and prompt referral to the vascular service for patient evaluation and expedited treatment may improve the current results related to limb salvage and overall patient survival. Currently, the treatment armamentarium is extensive and needs to be patient specific and driven by good clinical judgement. Alternatively, it is not unusual occasionally to find advanced ALEXI as an end-of-life event that is more appropriately treated in a hospice setting.

## References

1. Creager MA, Kaufman JA, Conte MS. Acute limb ischaemia. *N Engl J Med* 2012;366:2198-2206 [http://dx.doi.org/10.1056/NEJMcp1006054]
2. Earnshaw J. Acute ischaemia: Evaluation and decision making. In: Cronenwett J, Wayne K, eds. *Rutherford's Vascular Surgery*. 7th ed. Philadelphia, PA: Saunders Elsevier, 2010:2389-2398.
3. Callum K, Bradbury A. Acute limb ischaemia. *BMJ* 2000;320:764-767 [http://dx.doi.org/10.1136/bmj.320.7237.764]
4. Kasirajan K. Acute ischaemia: Treatment. In: Cronenwett J, Wayne K, eds. *Rutherford's Vascular Surgery*. 7th ed. Philadelphia, PA: Saunders Elsevier, 2010:2399-2411. [http://dx.doi.org/10.1016/B978-1-4160-5223-4.00158-X]
5. Ouriel K, Shortell CK, DeWeese JA, et al. A comparison of thrombolytic therapy with operative revascularization in the initial treatment of acute peripheral arterial ischaemia. *J Vasc Surg* 1994;19(6):1021-1030 [http://dx.doi.org/10.1016/S0741-5214(94)70214-4]
6. The STILE Investigators. Results of a prospective randomized trial evaluating Surgery versus Thrombolysis for Ischemia of the Lower Extremity (The STILE Trial).

*Ann Surg* 1994;220(3):251-268 [http://dx.doi.org/10.1097/00000658-199409000-00003]

7. Ouriel K, Veith FJ, Sasahara AA, et al. on behalf of the TOPAS investigators. A comparison of recombinant urokinase with surgery as initial treatment for acute arterial occlusion of the legs. *N Engl J Med* 1998;338:1105-1111. [http://dx.doi.org/10.1056/NEJM199804163381603]
8. Berridge DC, Kessel D, Robertson I. Surgery versus thrombolysis for acute limb ischaemia: Initial management. *Cochrane Database Syst Rev* 2002;3:CD002784.

## IN A NUTSHELL

- A patient with sudden onset of a cold, weak, numb and painful foot has acute lower extremity ischaemia (ALEXI) until proven otherwise. Labelling patients as acute gout, acute phlegmasia (deep vein thrombosis), acute sciatica, etc. may result in unnecessary delays in treatment, with tragic consequences.
- The rate of amputation is proportional to the delays in treatment. Peri-operative mortality is informed by the patient's medical comorbidities.
- All patients diagnosed with ALEXI need to be anticoagulated immediately. This applies especially to those being transferred to another centre for treatment, or being referred for a vascular opinion.
- There is no urgency in revascularisation of a patient with a Rutherford I ALEXI. Anticoagulate, investigate and treat appropriately electively.
- Non-viable limbs (Rutherford III) require amputation (usually an above-knee amputation). Occasionally, pre-operative angio-imaging informed revascularisation may be indicated for above-knee stump salvage. In select patients with multiple comorbidities and poor life expectancy, a non-interventional approach may be more appropriate.
- The strategies to treat ALEXI are complementary and generally multi-modal.
- Percutaneous endovascular strategies are indicated in Rutherford IIa patients.
- Rutherford IIb patients need immediate revascularisation, usually employing surgical or hybrid strategies. Percutaneous strategies that require 12 - 24 hours are inappropriate here, e.g. CDT.
- For embolic ALEXI, embolising lesions need to be diagnostically identified and treated on their own merits.
- Occasionally hypercoagulable states (cancer, antiphospholipid syndrome, heparin-induced thrombotic thrombocytopenia, etc.) may cause, and/or complicate a technically perfect revascularisation procedure in patients with ALEXI.

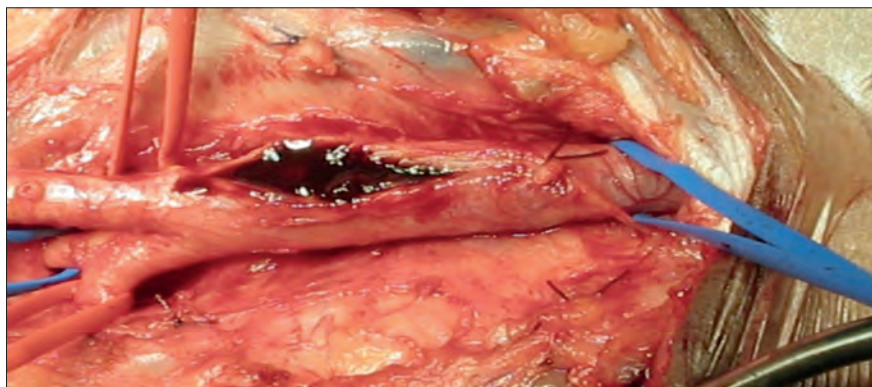


Fig. 3. Thrombus in the femoral artery.